

WHITEPAPER

Fractional Carbon Dioxide Laser and Plasmakinetic Skin Resurfacing

William F. Groff, DO, FAAD, Richard E. Fitzpatrick, MD, FAAD,
and Nathan S. Uebelhoer, DO, FAAD

NEOGENPLASMA

Fractional Carbon Dioxide Laser and Plasmakinetic Skin Resurfacing

William F. Groff, DO, FAAD,¹ Richard E. Fitzpatrick, MD, FAAD,¹
and Nathan S. Uebelhoer, DO, FAAD^{2,3}

¹Division of Cosmetic Dermatology, La Jolla, CA.

²Naval Medical Center San Diego, Dermatology Department, San Diego, CA.

³Scripps Clinic, Division of Dermatology, Cosmetic Dermatology Center, San Diego, CA.

Correspondence

William F. Groff,
Division of Cosmetic Dermatology, La Jolla Cosmetic Surgery Centre, 9850 Genesee Avenue, Suite 480, La Jolla, CA 92037.

Email: billygroff@hotmail.com

SUMMARY

Photodamage is one of the most common reasons that patients visit a dermatologist's office. Carbon dioxide (CO²) laser resurfacing has always been the gold standard for reversing photodamage. Because of the relatively high incidence of side effects and the prolonged downtime associated with CO² resurfacing, new technologies have emerged to address photodamage. Portrait skin regeneration (PSR) is a novel device that has been developed to treat photodamage, and this device yields fewer side effects and downtime than traditional CO² laser resurfacing. At our center, we have performed more than 500 high-energy PSR treatments and have developed a unique and highly effective treatment protocol. In addition, fractional CO² laser resurfacing has emerged as the latest technology developed to combat photoaging. This technology yields impressive results and is much safer and causes less downtime than traditional CO² laser resurfacing. In this article, we will review our treatment techniques and protocols as well as address patient selection, preoperative and postoperative care, and anesthesia.

The balance between downtime, persistent side effects, and predictability of effectiveness is paramount to creating the ideal laser. The unique skin resurfacing and rejuvenation achieved with fractional carbon dioxide (CO²) ablation and radio frequency-driven plasma heating lies within their ability to treat aggressively. Although our treatments yield postoperative downtimes that are generally longer than those observed with mid-infrared non-ablative fractional devices, the results appear, in our experience, to be superior for superficial tissue tightening and treating pronounced facial textural irregularities.

Furthermore, the efficacy approaches traditional full face resurfacing but does not require the same operator dependence to avoid catastrophic side effects. The mechanism of tissue injury and healing of these devices is unique and very different than traditional resurfacing, or chemical peels for that matter. It is for this reason that we suspect the incidence of significant and persistent side effects are dramatically less than these older methods of rejuvenation. Time will tell as they continue to undergo clinical research, but from our experience with these devices, their potential is quite promising.

ABLATIVE FRACTIONAL RESURFACING

For years, the 10.6- μ m ultrapulse CO₂ laser has dominated laser resurfacing because of its unparalleled efficacy in the improvement of photodamaged facial skin.

In combination with the 2940-nm Er:YAG, the most difficult facial textural irregularities can be addressed optimally including perioral lip and periocular lines, deep facial rhytides, acne scars, diffuse actinic keratoses, lentiginos, syringomas, and other benign adnexal tumors. Unfortunately, even in well trained hands, full-face laser resurfacing will result in erythema that will last 6 weeks or longer. Furthermore, the potential of permanent or delayed hypo-pigmentation and persistent hyperpigmentation is often the trade-off necessary for dramatic improvement in deep facial rhytides.¹

The degree of improvement and risk for persistent side effects correlates with the depth of resurfacing and the experience and expertise of the operator. The art of feathering the ablative field to blend with the untreated dyschromic skin takes precision and experience on the part of the operator, especially between the treated face and the untreated sun damage on the neck. Without proper feathering, ablative laser resurfacing can result in a line of demarcation, making it difficult to treat isolated cosmetic units. Because of these challenges, many laser operators, as well as patients, have moved away from ablative resurfacing and have turned to non-ablative means to rejuvenate sun-damaged or scarred skin. Although, in general, these non-ablative approaches have been safe, they have not been very predictable in producing appreciable results. To address the shortcomings of ablative and non-ablative devices, the Reliant Technologies (Mountain View, CA) developed the concept of fractional photothermolysis.

Fractional photothermolysis is characterized by the creation of microscopic zones of thermal damage with spatial separation between the columns of damaged tissue and the columns of untreated tissue. The depth of each column can be controlled by the pulse energy.² With non-ablative fractional resurfacing (covered in detail in this issue), a parallel column of heated, but not ablated tissue, extends down into the dermis. This non-ablative heated column heals from the periphery and, as long as the diameter of the column is very small, healing can occur without neovascularization. Reliant's non-ablative mid-infrared (mid-IR) device uses a 1550-nm Erbium-

doped fiber laser system that is capable of producing coagulated zones up to 1359 μ m in depth and with individual column diameters of less than 250 μ m.³ By performing multiple passes, the treated area can vary from 10% up to 40% of the total surface area of the skin. The same concept has been expanded into ablative fractional resurfacing by using the carbon dioxide wavelength of 10,600nm. Although other fractionated ablative devices are commercially available, this discussion will be limited to the two CO₂ devices with which the authors are most familiar: Reliant's Fraxel re:pair and the Encore (Lumenis, Santa Clara, CA).

In comparison with the mid-IR non-ablative fractionated devices, the CO₂ devices heat tissue much more intensely, causing vaporization of tissue while significantly heating adjacent dermal collagen. The immense volume of collateral heating causes thermal alterations of the helical structure of collagen molecules and results in tissue tightening.⁴ Uniqueto fractionated CO₂ tissue interactions is that, in addition to the thermally induced collagen tightening that is seen with traditional CO₂ facial resurfacing, tightening is also achieved by collapse of the small vaporized columns. As a consequence of these wound healing events, further tissue tightening continues during the next 3 to 6 months.⁵

In our experience, the use of the fractional CO₂ laser has yielded remarkable results in the treatment of photodamage, acne scarring, scarring from other causes, and dyschromia, as well as improvement in vascular ectasia. This is often achieved in a single treatment, but the improvement is cumulative with multiple treatments. The areas most commonly treated are the face, neck, and chest. However, treating isolated areas of any of these locations has been performed safely because of the fact that the treatment is done in a fractional manner and with multiple passes. By varying the number of passes, a gradual transitional zone can be easily created.

When treating facial photodamage, as well as photodamage of the neck and chest, we first assess the level of photodamage, which includes the number and depth of wrinkles, the amount of textural irregularity, the degree of dyschromia, the degree of capillary telangiectasia, and the degree of tissue laxity. For maximum results with moderate-to-severe photodamage, high-pulse energies are necessary to achieve tissue

tightening and significant rejuvenation of collagen in the dermis. High treatment densities are most likely to yield the most significant improvement. However, a secondary factor to consider is the healing time. Some patients may have significant photodamage but do not have the capability of taking a week off of work, so compromising the density of coverage may be necessary to enhance the speed of healing.

During the initial assessment, we also decide whether we will use other lasers in conjunction with the fractional CO₂. Combining fractionated lasers with other devices is specifically discussed further in this issue. In brief, the 595 nm-PDL, 532-nm KTP, or an IPL may be used for significant capillary telangiectasias. The q-switched alexandrite laser may also be used during the same treatment session for treatment of significant actinic dyschromia, lentiginos, or seborrheic keratoses. Traditional ablative settings can be used with a CO₂ or erbium laser to address more pronounced vertical rhytides of the upper and lower lip, as well as to ablate epidermal lesions, such as seborrheic keratoses or significant actinic keratoses. Multiple passes of traditional non--fractional ablative resurfacing may be required for vertical rhytides on the upper and lower lip.

Another factor to consider pre-operatively is the method of anesthesia. Anesthesia choices include topical xylocaine-tetracaine preparations, nerve blocks, local infiltration with xylocaine, oral or intramuscular sedatives and pain medications, intravenous sedation, or general anesthesia.

Infections can occur with ablative fractional resurfacing but are a relatively uncommon occurrence. We routinely use valacyclovir for herpes simplex prophylaxis, and we will

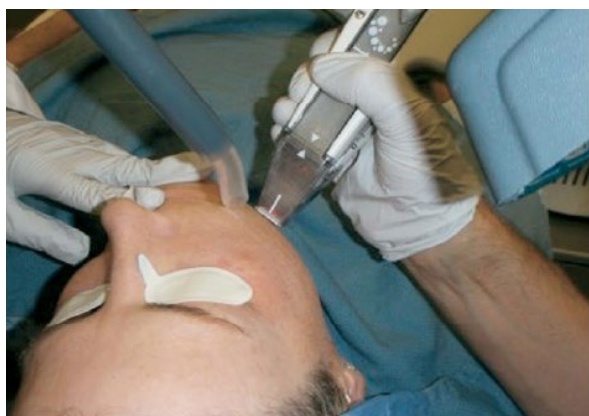

FIGURE 1
Application of Fraxel re:pair to patient's skin in conjunction with Zimmer air cooler.

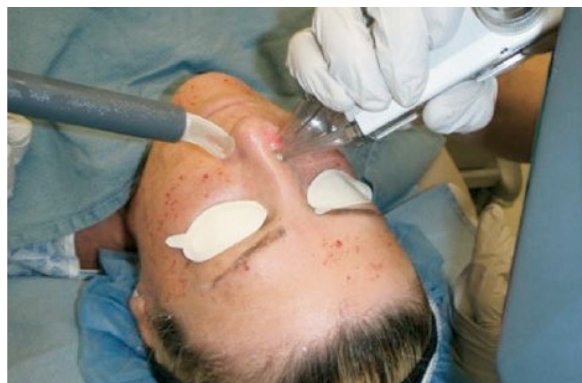


FIGURE 2
Visible pinpoint bleeding with a higher pulse energy (40mJ) treatment.

also use systemic antibiotic coverage when using densities of 20% or greater. Soaking the treatment area with cotton gauze saturated with a mixture of 8 ounces of cool water mixed with 1 tsp. of white vinegar helps débride the surface crusting and facilitates rapid healing. This can be done as frequently as every 2 hours. It is not essential to do this, but it does give the patient comfort, as well as promoting more rapid healing. We routinely use Skin Medica (Carlsbad, CA) TNS Recovery Complex to assist in stimulating collagen on a twice-daily basis for the first 3 months after treatment as well as SkinMedica Ceratopic Lotion to re-establish the lipid barrier function of the epidermis.

FRAXEL RE:PAIR

Reliant has lead the way in terms of initiating fractional resurfacing and, in December 2007, the Fraxel re:pair fractionated CO₂ became commercially available. The Fraxel re:pair has a penetration depth that varies from 300m up to 1579m. The depth of the heated tissue is determined by the pulse energy. Maximum pulse energy is 70 mJ. Treatment densities may be adjusted from 5% up to 50% by choosing higher treatment levels and by making multiple passes.

If the patient has mild photodamage, we may choose to treat using a treatment density of 25% to 30% and a mid-range pulse energy of 20 mJ, which penetrates 644m. This is accomplished by rolling the device in contact with the skin (Fig. 1) and performing double passes over the same pathway for a total of 2 passes, and then 2 passes at 90-degree angles over the same area for a total of 4 passes. It is quite easy to see the passes as they are applied to the skin, and this is done in a meticulous and very even manner. As the pulse energy is increased,

pinpoint bleeding can become visible (Fig. 2). This is never clinically significant, but it does create an unsightly image for the patient during the first 24 hours. A small tip is available for treating more confined surface areas, such as the eyelids or the nose. Treatment of the facial area typically requires approximately 20 minutes, treatment of the neck requires an additional 15 to 20 minutes, and treatment of the chest an additional 5 to 10 minutes. Because the primary pain sensation is secondary to intense heat, we use the Zimmer Air Cooler in conjunction with the treatment and find this to be very helpful in minimizing pain and discomfort (Figs. 1 and 2).

If a patient is treated at 10% coverage, they will develop a fine grainy crust over the surface that is sparse and heals rapidly, generally within 3 to 4 days. If a high density of 35% to 50% coverage is used, then this grainy crust will cover essentially the whole face and will usually take about a week to resolve. There will be facial erythema that lasts anywhere from 2 to 6 weeks, depending on the treatment density and the pulse energy. The neck and chest typically heal more slowly and develop a bronze, dry grainy surface that peels after 10 to 12 days. It is very common for the chest and neck to be pruritic during the healing, especially during the first 2 to 4 weeks, and often antihistamines or a topical steroid cream may be necessary to decrease the symptoms. Significant tightening of eyelid skin is very common, and will improve gradually over about a 6 month period and may result in at least 2 to 3 mm tightening of the tissue (Fig. 3).

When high-pulse energies are used on the eyelids, there may be subcutaneous bleeding and purpura. We always use corneal shields when working around the eyes (Fig. 4). Decreasing the pulse energy to 30 mJ instead of the maximum of 70 mJ may be advisable in this area until further studies have been completed. The second area, other than the eyelids, where the fractional CO₂ laser is dramatically superior to most other technologies, is the cheeks (Fig. 5). When treating severe photodamage, pulse energies of 50 mJ to 70 mJ are used and treatment densities of 40% to 50% are used. We do not recommend exceeding 50% coverage on the face. When treating the neck, there is a gradual decrease in the treatment densities as high treatment densities are not well tolerated on the neck, and the risk of scarring is greater with high treatment densities. Treating the sub-mental area can be accomplished at virtually the same densities as the face, but we do not recommend exceeding 35%

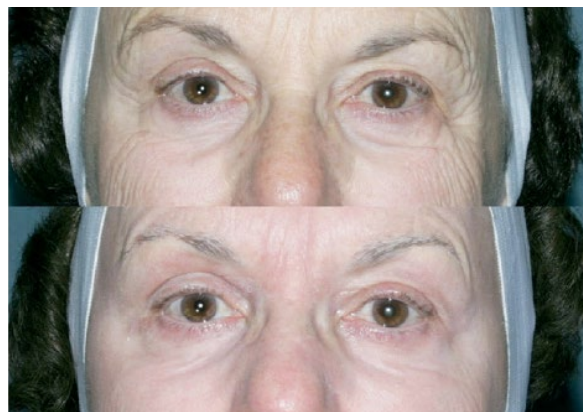

FIGURE 3

A before and after photo of our patient showing significant tightening of the eyelids and periorbital rejuvenation. Patient was treated at 30 mJ and 50% coverage.

densities on the sub-mental and upper neck areas. In the mid neck, densities of 25% to 30% can be used safely, but on the lower neck we do not recommend exceeding densities of 20%. For treatment on the chest, a maximum density of 20% is recommended.

Higher pulse energies are used for more severe photodamage. Pulse energies, as high as 70 mJ, have been used safely on the neck. More commonly, we use pulse energies in the 20 mJ to 30 mJ range for both the neck and the chest.

Poikiloderma on the neck and chest will also respond significantly to the fractional CO₂ laser (Fig. 6), and elimination of mats of telangiectasias is commonly seen using the Fraxel CO₂ laser alone. However, when we have patients with significant vascular components, we will commonly use a PDL or KTP laser immediately before ablative fractional resurfacing. The q-switched alexandrite laser can also be used to eliminate discreet

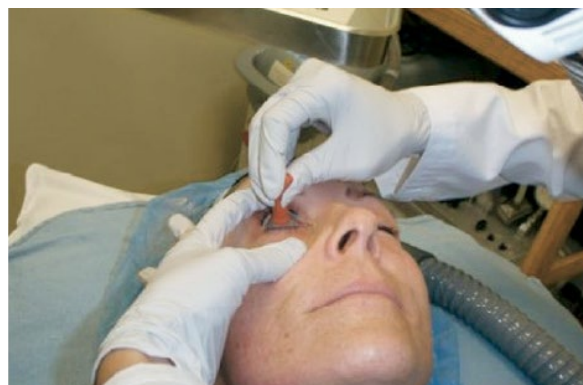
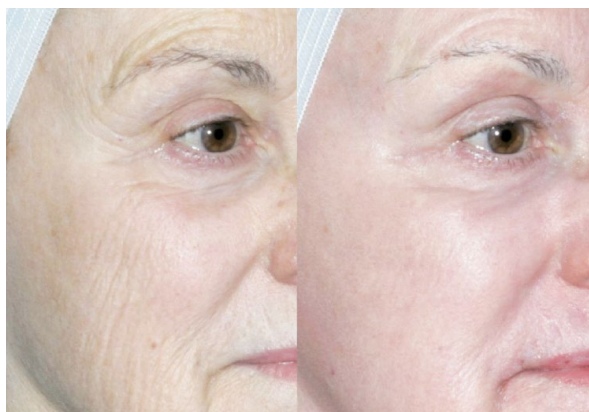
FIGURE 4

Application of corneal shields to protect the eyes during treatment.

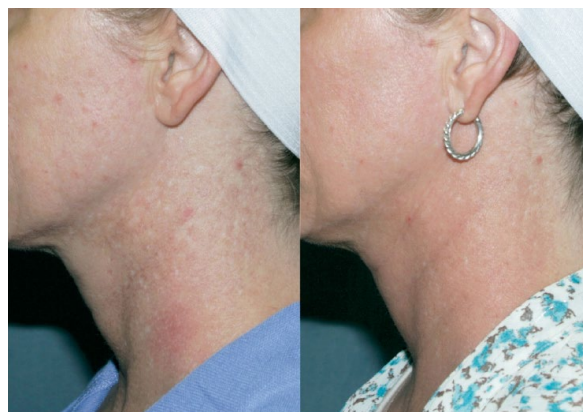**FIGURE 5**

Dramatic improvement of rhytids of the cheek. Treatment settings were 50 mJ and 50% coverage.

or larger areas of lentigines and seborrheic keratoses on the face, neck, and chest. This can be done immediately before treatment or immediately following fractional CO₂ treatment. If traditional ablative resurfacing lasers are required to sculpt away deep lines of the upper and lower lip, the fractional CO₂ laser is carried right up to the border of the fully ablated area. We have not seen dyschromic demarcation problems in these transitional areas (Fig. 7).

Notable skin tightening over the cheek subunits after Fraxel re:pair treatment is common. Treatment of the cheeks can be accomplished without causing hypopigmentation and without causing a line of demarcation, as treatment continues from the face and jaw line to the neck. Significant tissue tightening can occur on the neck, but is more difficult to achieve. However, hypopigmented areas from acne scarring commonly re-pigment during healing (Fig. 6). These scars and hypopigmented areas are commonly seen on the lower cheeks and upper neck.

In addition to the treatment of dyschromia, poikiloderma, and photodamage of the lower cheeks, neck, and upper chest, we have found the Fraxel re:pair to be very effective for the treatment of acne scars. Recent studies have confirmed its safety and efficacy.^{6,7} In treating acne scars or scars of any etiology, penetration to the depth of the scar gives significantly greater potential for improvement. Treating at a higher density allows better tissue tightening as well as blending of scars. Whenever possible, we will treat virtually all scars at a pulse energy of 70 mJ and use the highest density that is safe for the area being treated. It is not necessary to treat the adjacent areas at the same density unless tissue

**FIGURE 6**

Improvement in poikiloderma and hypopigmented maculae. Treatment settings were 40 mJ and 15% coverage.

tightening is considered to be a primary goal. Therefore, when we are treating acne scars on the forehead and cheeks, we typically treat the whole area using a high pulse energy. If there are isolated scars on the neck or chest or isolated scars on the medial cheeks, then treating only the scarred area at the higher-pulse energy can be done and subsequently using a lower pulse energy and lower density on the adjacent skin.

Melasma is a condition which continues to be a challenge to treat with lasers and light-based technologies, particularly in patients with Fitzpatrick skin types 3 and 4. We have been very pleasantly surprised by the significant improvement that we have seen when treating this condition with the Fraxel re:pair (Fig. 8). Our goal is not to achieve total elimination of melasma but to attain better blending of color discrepancies, without obvious patchy pigmentation. Our most successful treatment parameters have been pulse energies between 30 to 40 mJ and treatment densities of 30% to 40%. A single treatment session using the parameters is preferable to a series of lower-intensity treatments.

When treating acne scars, there is significant improvement seen 1 or 2 weeks after the treatment (Fig. 9). Some of this improvement may be secondary to swelling and will subside to some extent during the next month. However, as with traditional resurfacing, new collagen formation requires longer than a month and a second phase of improvement in these scars will occur up to 6 months after the treatment. If a second treatment is necessary, it is best to wait a minimum of 3 months between the treatments to assess the degree of improvement from the initial treatment session.

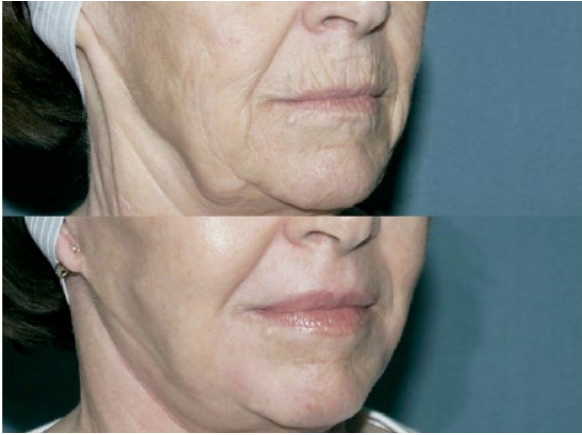

FIGURE 7
There is no line of demarcation between the perioral region, which was treated with CO₂ and erbium resurfacing, and the cheek. The cheek was treated with the Fraxel re:pair.

However, it is not harmful to retreat an area before this 3 month window, but consideration needs to be given to the density that is used. If the cumulative density of the 2 treatments still remains less than 50%, then the 2 treatments can be done at any interval, but if a high density treatment is used in the 40% or 50% range, we would recommend waiting a minimum of 2 to 3 months before considering a 2nd treatment session.

ENCORE ACTIVEFX AND DEEPFX

In early 2006, Lumenis released a new version of the UPCO² (Encore, Lumenis, Santa Clara, CA) with a smaller beam diameter (1.3 mm) and an option for more random and less dense patterns of ablation. In our experience,

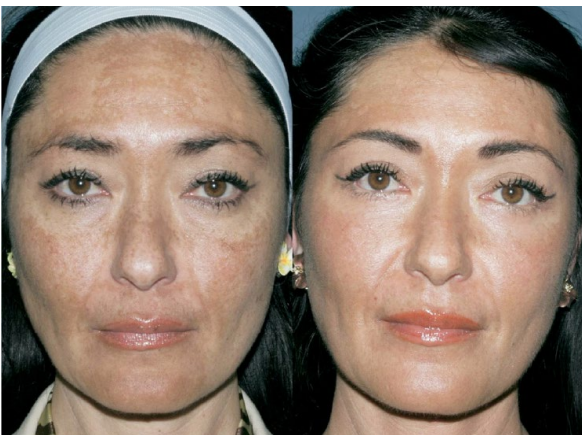

FIGURE 8
Significant improvement in melasma 3 months after a single treatment at 40 mJ and 30% coverage.

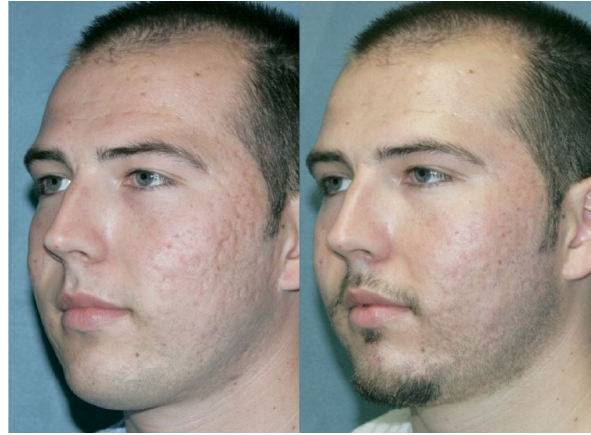

FIGURE 9
Significant improvement in acne scars 3 months after a single treatment at 50 mJ and 35% coverage.

using the lowest density settings with the 1.3 mm column diameter (termed 'Active FX' by the company) results in excellent improvement in lentigines with a relatively short downtime. In addition, the density can be increased to a more typical ablative setting and the pattern footprint sized exactly to match individual lentigines. This, in our opinion, is the most important advantage of this new generation CO₂. Light lentigines can be difficult to clear with visible and near-IR lasers (such as the q-switched 532 nm or 755 nm) and are often recalcitrant to fractional non--ablative laser treatments as well. If the patient requests clearance of these lentigines, which is often the case, then they may be more willing to accept 5 to 7 days of crusting followed by 7 more days of focal erythema to the few selected areas. Typically, we treat 5 to 10 of the most prominent or troublesome lentigines at 90 mJ using the round pattern with a density of 4 to 5 and a footprint of less than 5 mm. This is then followed with a full facial treatment using "Active FX" settings depending on how much downtime the patient can tolerate (Fig. 10).

There are 2 main differences between the ActiveFX and other fractional ablative devices. First, the total facial surface area percentage of ablation at the lowest density setting is greater than 50%. Second, the depth of ablation is much less, being confined to the epidermis with some thermal diffusion limited to the papillary dermis. In late 2007, Lumenis released a "stamping" style micro scanning handpiece that could be attached to the Encore UPCO² (Fig. 11). This "DeepFX" handpiece fractionated the beam diameter to 0.12 mm. This converted the volume of ablation per mJ of energy from a shallow but wide ablative cylinder (ActiveFX) into a thin deep ablative column for

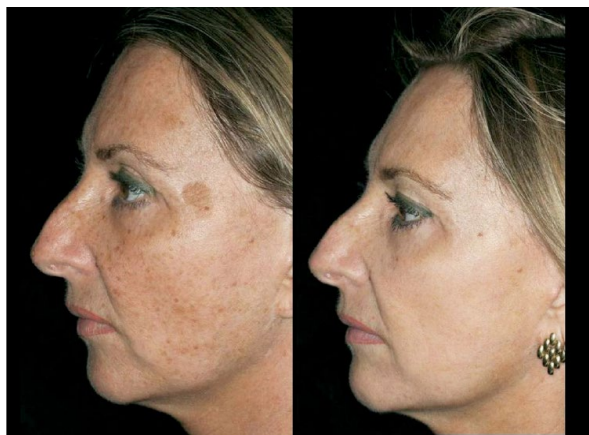

FIGURE 10
Active FX: CPG settings: 3 to 6-3; 100 mJ fluence; 125 Hz; double pass on periorbital region (Courtesy of Matteo Tretti Clementoni, MD).

penetration depths into the dermis while only ablating 5% of the surface area of the face with a single pass.

With the addition of the DeepFX handpiece, the Encore has been extremely versatile in our practice with a spectrum of options from full face ablative resurfacing to fractional resurfacing. By using multiple settings and passes on various areas of the face, anywhere from 5% to 100% of the skin can be ablated, depending on how aggressive we want to be in each cosmetic unit or lesion. Our typical treatment will combine a full face first pass DeepFX followed by localized treatments with Active FX and fully ablative settings targeting rhytides and lentiginos, respectfully (Figs. 10 and 12). To diminish the rhytides of the periorcular or perioral areas we occasionally use multiple passes or higher densities (density settings 3-5). This approaches traditional resurfacing and the results are predictable and impressive (Figs. 13 and 14).

Although the spacer is disposable (Fig. 15) the cost is inconsequential, making consumables a non--issue. The



FIGURE 11
Fractional "DeepFX" Microscanner attachment for Lumenis Encore CO2 (Courtesy Lumenis Corp., Santa Clara, CA).

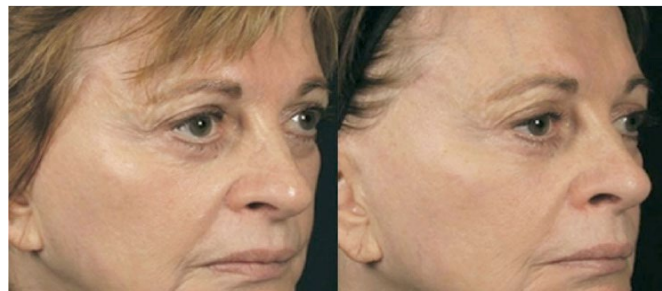

FIGURE 12
Before (left) and after (right) 1 treatment with 6-week follow-up DeepFX (15 mJ; density 1; one pass) immediately followed by ActiveFX (80mJ; density 1; one pass) (Courtesy of Robert Weiss, MD).

disadvantages of the Encore are related to the somewhat cumbersome stamping style DeepFX handpiece compared with the rolling-type handpiece seen with the Fraxel Re:pair fractionated CO². It requires more technical skill to lay down rows in a uniform array without skipping areas. This takes time and meticulous observation until the operator is familiar with the faster repetition rate.

There have been no head-to-head ablative fractional comparison studies to date as this technology is just emerging. However, as a stand alone device, the Encore has the widest range of ablative settings commercially available from any device. Nevertheless, the efficacy of these devices will likely all be quite similar depending on the familiarity with the device by the operator.

PLASMAKINETIC RESURFACING

Portrait Skin Regeneration (PSR; Portrait, Rhytec, Inc., Waltham, MA) is a novel skin rejuvenation technology that uses radiofrequency (RF) to convert nitrogen gas into a high energy state of matter called plasma. Electrons are stripped from molecules in the nitrogen gas, ionizing the gas and creating plasma. Energy is stored in the long vibrational states of the nitrogen molecules. The plasma pulse emerges from the tip of the treatment handpiece as a beam and is directed onto the skin without the treatment tip contacting the treatment area (Fig. 16). Each plasma pulse carries a known amount of heating energy and is adjustable by the treating physician from 1.0 to 4.0 J. This change in pulse energy is accomplished by changes in the pulse width from 5.20 to 15.40 milliseconds. Treatment spot diameter, using the same criterion that is used for a laser Gaussian profile, is about 10mm. Light-based resurfacing devices, such as the CO² and Er:YAG laser, require a target material (chromophore)

that absorbs energy at the wavelength of the light source. The heating of elastin and collagen occurs because heat conducts from the chromophore material (typically water for skin re-surfacing lasers) to the surrounding tissues. In contrast, plasma skin resurfacing requires no chromophore because tissue heating occurs directly. With the PSR device, energy setting, delivery time, beam size and lack of RF coupling to the skin are such that there is uniform heating and no ablation of the skin. The plasma energy causes part or all of the epidermis to become non-viable; however, the epidermis stays intact for the first few days post operatively, acting as a biologic dressing until peeling begins in 3 to 4 days.

Studies comparing plasma kinetic resurfacing to traditional ablative laser resurfacing have shown comparable results with a lower cost and side effect profile.⁸⁻¹⁰ Histological studies have demonstrated a predictable pattern of dermal collagen remodelling,^{10,11} and numerous clinical studies have shown safely and efficacy for the treatment of various facial textural irregularities.^{9,12-14} The PSR device was subsequently cleared by the United States Food and Drug Administration for multiple single-pass, low energy treatments of facial rhytids and single pass, high energy treatment of facial rhytids, as well as the treatment of acne scarring, superficial skin lesions, including seborrheic keratoses and actinic keratoses.

In our practice, the PSR device has been an excellent alternative and adjunctive treatment to the fractionated and ablative lasers. PSR technology can be used at different energies for varying depths of effect, from superficial epidermal sloughing to deep dermal heating. Areas that may be treated with the device include the face, scalp, neck, chest, and hands. We have performed more than 500 high energy face treatments at our center

and have developed a unique high energy facial treatment technique (Fig. 17). This protocol maintains the excellent safety profile of the current protocols, and will be the focus of our article.

The current PSR high energy protocols that are taught and used include a single pass high energy treatment and a double pass high energy treatment. These protocols use non-overlapping pulses of plasma energy to resurface the facial skin. In these protocols, each plasma pulse is placed on the skin in a non-overlapping fashion and the total pulse count, in general, is below 1200 pulses. These protocols use lower pulse energies in the periorbital region as well. Our treatment protocol is different because we use overlapping pulses. Each pulse overlaps approximately 20% when interacting with pulses that have been previously delivered below and adjacent to the pulse we are delivering. We also use high pulse energies (3.0-4.0 J) on the upper and lower lids. Our total pulse counts are between 1500 and 1900 pulses per patient. Patient selection is very important when deciding which patients will respond best to our protocol. We generally reserve these treatments for patients with Fitzpatrick I, II, and III skin types. In this patient population, the PSR device is excellent for treating facial wrinkles, photodamage, textural irregularities, solar lentigines, pigmentary discrepancies, acne scarring, actinic keratoses, and seborrheic keratoses. All patients treated with PSR in our practice are pre-operatively started on oral antibiotics, antivirals, and anti-fungal agents to minimize the chance of infection, which can lead to delayed healing and possibly scarring. These are usually started the day before the procedure. A regimen that we commonly employ is minocycline 100 mg PO twice per day for 7 days, valacyclovir 500 mg PO twice per day/ three times per day for 10 days, and fluconazole 100 mg PO QD for 5 days. We will use the 3 times per day dosing of valacyclovir in patients with a history of herpes labialis.

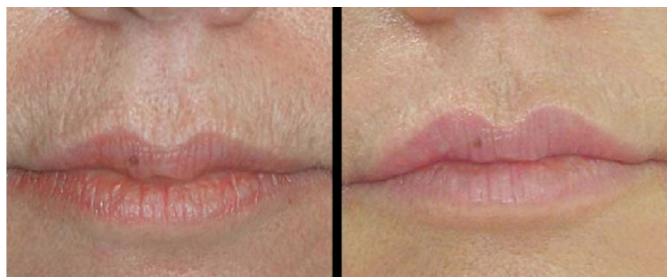

FIGURE 13
Combination of 'ActiveFX' and 'DeepFX' treatment of perioral lip rhytides (Courtesy of Robert Weiss, MD).

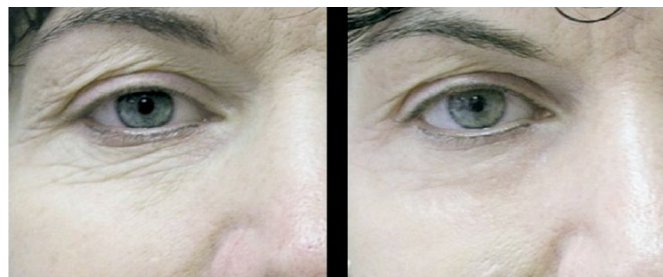

FIGURE 14
Combination of 'ActiveFX' and 'DeepFX' treatment of periocular lid rhytides (Courtesy of Glenn DeBias, DO).



FIGURE 15
“DeepFX” disposable tip.

On the day of the procedure, the patient’s skin is prepped by washing the skin with an antibacterial soap. After the skin is dry, we apply a 23% lidocaine and 7% tetracaine ointment onto the face, and the patient waits for 60 minutes while the anesthesia takes effect before the treatment. To augment the effects of this numbing ointment, our patients are given a choice of oral (PO) or intramuscular (IM) pain relievers. Our favorite combination is 25 to 100 mg of meperidine IM with 50 to 75 mg of vistaril IM about 45 minutes before the start of the procedure. We also like to give the patient a PO anxiolytic at that time, either lorazepam or diazepam. We will sometimes use PO narcotics instead of the IM medications, but our experience has shown that the IM medications work the best. Occasionally, ketorolac 30 to 60 mg IM is substituted for narcotics based on the individual needs of the patient.

After an application period of 60 minutes, the numbing ointment is wiped off and the skin is prepped with chloroxylenol 3% surgical cleanser. Two drops of

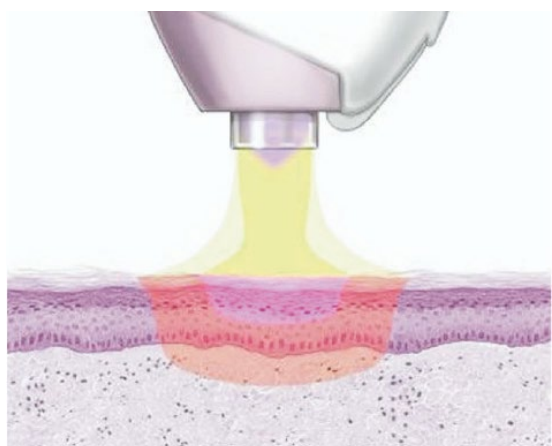


FIGURE 16
Noncontact delivery of plasma pulse is shown.

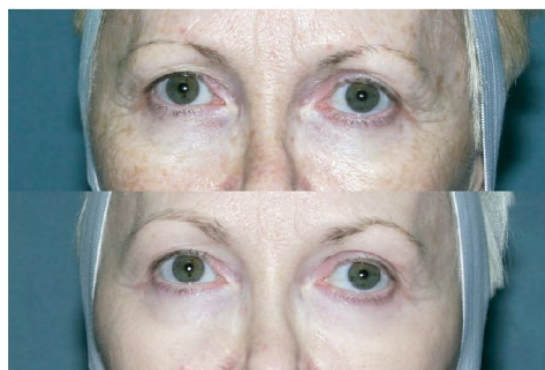

FIGURE 17
Before and 3 months after 1 high energy full face PSR treatment is shown.

proparacaine ophthalmic solution 0.5% are instilled into each eye and black plastic internal eye shields are placed to protect the eyes during the treatment. This safety step is paramount because we are treating at high energy on the upper and lower lids, right up to the lash lines. Next, we perform nerve blocks (supraorbital, supratrochlear, infraorbital, and mental) using a 50:50 mixture of 1% xylocaine without epinephrine in combination with 0.5% bupivacaine with epinephrine. Xylocaine 1% with epinephrine is used to infiltrate the upper and lower lids. We also do some diffuse infiltration in the subcutaneous plane on the lateral cheeks with a dilute solution of xylocaine. To make this dilute solution, we take 3 mL of 1% xylocaine with epinephrine and mix it with 7 mL of 0.9% NaCl in a 10-mL syringe. Next, we use a tan or black eyeliner to draw grids on the face to mark out different zones of treatment with the PSR device (Fig. 18). These grids help us to ensure we are fully and evenly covering the entire face. Ultrasound gel is placed on the eyebrows, eyelashes, and along the hairline to protect the hair from the peripheral heat of each pulse placed in close proximity to these locations. A strategically placed tongue depressor can also help deflect any heat from damaging the hair follicles.

The treatment is initiated at the inferior border of the chin and proceeds along the jaw line toward the ear, administering pulses along the jaw line at 2.5 J. We will usually do a few rows of 2.5-J passes and each pulse is overlapped approximately 10% to 20%. Next we will treat the area just in front of the ear, and again this will be treated with 2.5 J (Fig. 19). As we apply the pulses in a caudad to cephalad direction, each row of pulses move toward the central face, and the pulse energy is increased from 2.5 J up to 4 J. It is important to perform

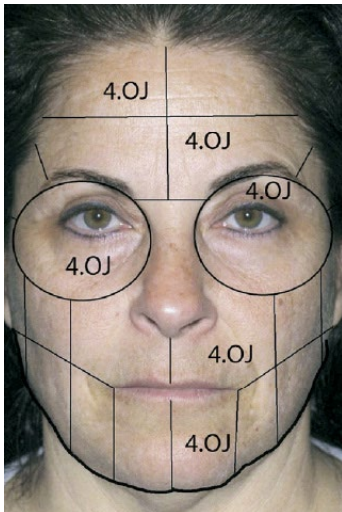


FIGURE 18
Black eyeliner is used to mark out treatment grids.

long continuous rows of pulses and avoid placing pulses in a cluster, as this clustering can lead to bulk heating and subsequent delayed healing. Typical repetition rate is no greater than 2.0 Hz and, if the treating physician is new at performing the procedure, we recommend treating at 1.5 Hz or slower for the first several cases. The periorbital area, including the upper and lower lids, are treated at 3.0 to 4.0 J and the forehead and nose are treated at 3.5 J to 4 J, with each pulse overlapping 10% to 20% in both the horizontal and vertical plane. After the treatment is completed, 44cm gauze that has been soaked in a dilute vinegar solution (1 teaspoon of vinegar in 8 ounces of water) is placed onto the treated skin for 20 to 30 minutes. This treatment not only soothes the patient's skin, but it also has antibacterial properties. A thin layer of Glucan Pro Cream 3000 (Brennen Medical, Inc., St. Paul, MN) is applied over the treatment area. The patient is usually seen for their first follow-up the next day or, if the patient's treatment is done on Friday, then we will see them on Monday. We recommend that our patients do dilute vinegar soaks every 2 hours while they are awake, and we have them apply a thin layer Glucan cream to their skin in between these soaks. After the patient has completely peeled and re-epithelized, we have them start on a skin care regimen which consists of twice-daily application of Skin Medica TNS Recovery Complex, TNS Ceramide

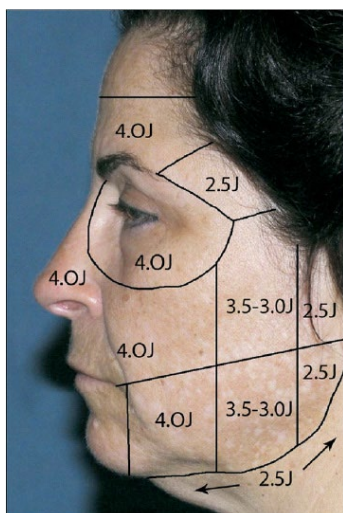


FIGURE 19
Grids show different treatment energies used on different regions of the face.

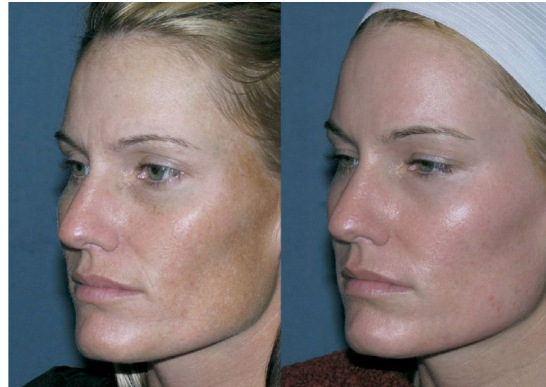

FIGURE 20
Before and 6 weeks after 1 PSR treatment are shown.

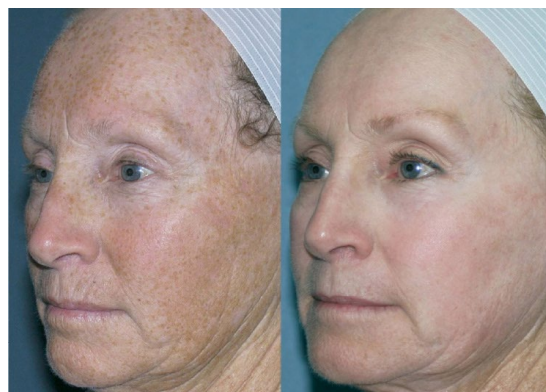

FIGURE 21
Before and 3 months after 1 PSR treatment are shown.

Treatment Cream and sunblock with zinc oxide and/or titanium dioxide.

With our unique PSR treatment technique, we have had tremendous success at treating photodamage on the facial skin (Fig. 20). If a patient suffers from solar lentigos, seborrheic keratoses, and/or actinic keratoses, these will be 90% to 100% cleared with one treatment using our protocol (Fig.21). Wrinkles improve 50% to 100%, depending on depth and location (Fig. 22). Patients frequently experience dramatic skin tightening in the periorbital region, and this is often the area that truly shows a patient's age (Fig. 23).

The periorbital region has often been a difficult area to improve, unless using the CO² laser. The PSR device has several advantages over traditional CO² laser resurfacing. Social downtime is only 6 to 7 days, the risk of infection, hyperpigmentation, and prolonged erythema is significantly less, and there have been no cases of hypo-pigmentation. With PSR treatment, patients will see an immediate improvement, followed by continuous

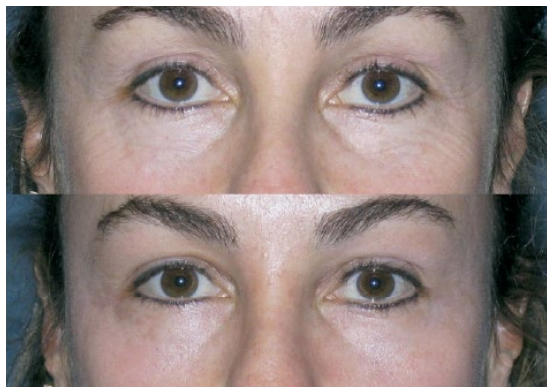

FIGURE 22
Before and 4 months after 1 PSR treatment are shown.

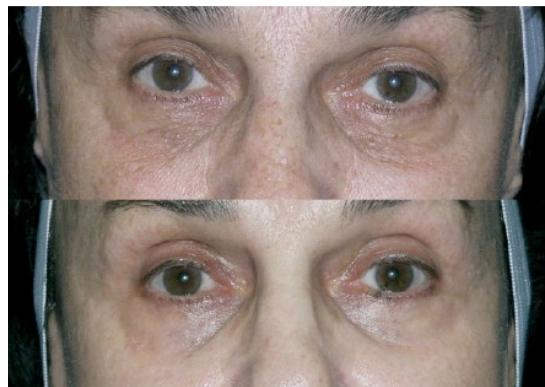

FIGURE 24
Dramatic tightening and textural improvement of lower lids 6 months after 1 PSR treatment are shown

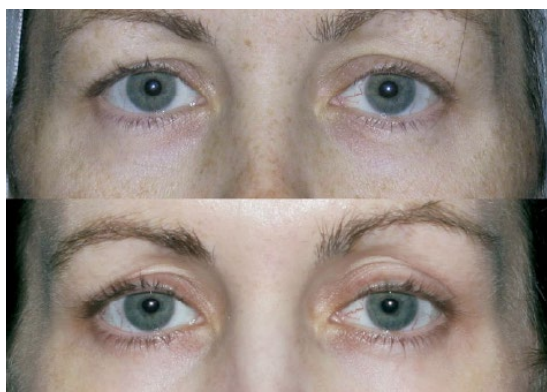

FIGURE 23
Dramatic tightening of the upper lids 3 months after 1 PSR treatment are shown.

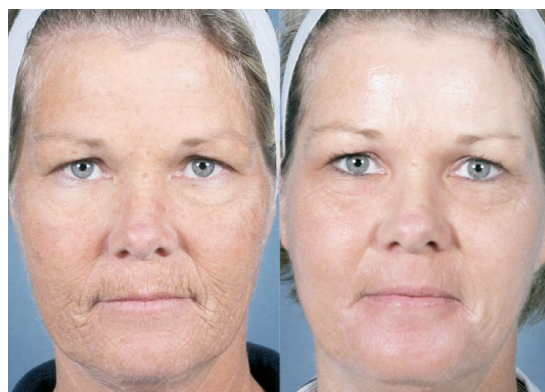

FIGURE 25
Before and 3 months after full face PSR (except peri-oral area) and peri-oral CO₂ laser resurfacing are shown.

improvement in wrinkles, texture and skin tightening for at least 6 to 12 months. Although the PSR device can soften vertical rhytids on the upper lip, the only way to predictably erase and sculpt away these lines is with the CO₂ laser. In our practice, if a patient has vertical upper lip rhytids, we will often combine the CO₂ laser with PSR in the same patient. The area of the upper lip treated with the CO₂ blends perfectly with the PSR-treated skin (Fig. 24).

Some patients experience improvement in facial telangiectasias with PSR treatment. If a patient has diffuse telangiectasias on the face, we will treat these areas with a 595 nm pulsed dye laser or a 532 nm KTP laser just before our PSR treatment. Lastly, it is important to note that while the PSR is an excellent tool for treating the neck, chest, and hands, the fluences for these areas are much lower and our high energy facial protocol should not be used on these areas (Fig. 25).

CONCLUSION

Advances in technology have provided dermatologists with new devices, such as fractional CO₂ lasers and the plasma skin regeneration device, which enable us to treat photodamage and scarring in a predictable, efficacious, and safe manner. Traditional CO₂ laser resurfacing has been the gold standard, yet these devices can provide results that approach and in some circumstances exceed the results of the standard CO₂. These newer technologies also dramatically reduce the downtime as well as the side effect profile when compared to standard CO₂ resurfacing. In our experience, patients are opting for these new treatments over non-ablative resurfacing because the results are significantly better, more predictable, and have a very good safety profile. In the future, the role of these devices will continue to expand as our experience grows.

REFERENCES

1. **Nanni CA, Alster TS:** Complications of carbon dioxide laser resurfacing. An evaluation of 500 patients. *Dermatol Surg* 24:315-320, 1998
2. **Bedi VP, Chan KF, Sink RK, et al:** The effects of pulse energy variations on the dimensions of microscopic thermal treatment zones in nonablative fractional resurfacing. *Lasers Surg Med* 39:145-155, 2007
3. **Manstein D, Herron GS, Sink RK, et al:** Fractional photothermolysis: A new concept for cutaneous remodeling using microscopic patterns of thermal injury. *Lasers Surg Med* 34:426-38, 2004
4. **Hantash BM, Bedi VP, Chan KF, et al:** Ex vivo histological characterization of a novel ablative fractional resurfacing device. *Lasers Surg Med* 39:87-95, 2007
5. **Hantash BM, Bedi VP, Kapadia B, et al:** In vivo histological evaluation of a novel ablative fractional resurfacing device. *Lasers Surg Med* 39:96-107, 2007
6. **Ortiz A, Elkeeb L, Truitt A, et al:** Evaluation of a novel fractional resurfacing device for treatment of acne scarring. *Lasers Surg Med* 31:79, 2008 (suppl 20)
7. **Hale EK, Sukal S, Bernstein L, et al:** Ablative fractional resurfacing for the treatment of acne scarring. *Lasers Surg Med* 31:80, 2008 (suppl 20)
8. **Potter M, Harrison R, Ramsden A, et al:** A randomised control trial comparing plasma skin resurfacing (PSR) with carbon dioxide laser in the treatment of benign skin lesions. *Lasers Med Sci* 18:S1-S67, 2003 (suppl 1)
9. **Fitzpatrick R, Geronemus R, Kim K, et al:** Plasmakinetic skin rejuvenation on perioral rhytides. *Lasers Surg Med* 16:33, 2004 (abstr) (suppl 16)
10. **Fitzpatrick R, Bernstein E, Iyer S, et al:** A histopathologic evaluation of the plasma skin regeneration system (PSR) versus a standard carbondioxide resurfacing laser in an animal model. *Lasers Surg Med* 40:93-99, 2008
11. **Fitzpatrick R, Holcomb JD, Sibbons P:** Unique two-step neocollagenesis response using plasma energy for wrinkle reduction and skin rejuvenation. *Lasers Surg Med* 34:90, 2008 (suppl 20)
12. **Bogle MA, Arndt KA, Dover JS:** Evaluation of plasma skin regeneration technology in low-energy full-facial rejuvenation. *Arch Dermatol* 143:168-174, 2007
13. **Biesman B:** Plasmakinetic Resurfacing of the Eyelids. *Lasers Surg Med* 34:89, 2008 (suppl 20)
14. **Gonzalez M, Sturgill W, Ross E, et al:** Treatment of acne scars using the plasma skin regeneration (PSR) system. *Lasers Surg Med* 40:124-127, 2008

All images used with permission from customers.

What is NeoGen Plasma?

Bought to you by Energist, NeoGen Plasma provides cost effective, clinically proven treatments that halve patient downtime.

This patented nitrogen plasma technology, spun out from a leading MedTech University, is the safer alternative to ablative treatments. Over 120,000 treatments have been performed world-wide with zero adverse incidents.

[HOW THE TECHNOLOGY WORKS](#)

NEOGENPLASMA